

Use of the Hammersmith Infant Neurological Examination in infants with cerebral palsy: a critical review of the literature

DOMENICO M ROMEO | DANIELA RICCI | CLAUDIA BROGNA | EUGENIO MERCURI

Paediatric Neurology Unit, Catholic University, Rome, Italy.

Correspondence to Eugenio Mercuri, Pediatric Neurology Unit, Catholic University, Largo Gemelli 8, 00168 Rome, Italy. E-mail: mercuri@rm.unicatt.it

This article is commented on by Haataja on page 219 of this issue.

PUBLICATION DATA

Accepted for publication 8th July 2015.

Published online 25th August 2015.

ABBREVIATIONS

HINE Hammersmith Infant Neurological Examination

The Hammersmith Infant Neurological Examination (HINE) has been proposed as one of the early neurological examination tools for the diagnosis of cerebral palsy (CP). The aim of the present study was to critically review the existing literature and our experience with the use of the HINE in infants at risk of CP. The published papers confirm that the HINE can play an important role in the diagnosis and prognosis of infants at risk of developing CP, and provide information on aspects of neurological findings impaired in different forms of CP and brain lesions.

Cerebral palsy (CP) identifies a group of developmental disorders of movement and posture, causing activity limitation, attributed to non-progressive disturbances related to brain injury early in development.^{1,2} Establishing an early diagnosis of CP is important as this can lead to early intervention, thereby maximizing the opportunities for appropriate physical and learning support.³

An early diagnosis of CP based on early neurological assessments is not, however, always easy because of the possibility of false-negative and false-positive results. False negatives are generally due to a latency period between the occurrence of the lesions and the onset of clinical signs of CP. False positives, in contrast, are possible in infants at risk of CP as they often have a complicated perinatal or postnatal course, with several factors such as prematurity or birth asphyxia that can cause transient neurological abnormalities not always related to long-term sequelae.

The Hammersmith Infant Neurological Examination (HINE),⁴ has recently been proposed as one of the early neurological examination tools for the diagnosis of CP.³ It is a simple and scorable method designed for evaluating infants between 2 months and 24 months of age. It includes 26 items that assess different aspects of neurological examinations such as cranial nerves, posture, movements, tone, and reflexes.⁴ The pro forma provides instructions for performing the individual items and diagrams to aid recording. The HINE is easily performed and accessible to all clinicians; it can be completed in 5 to 10 minutes. A good interobserver reliability has been reported, even in inexperienced staff.⁴

Although the HINE was originally developed as a clinical tool, an optimality score was also developed for research purposes. The optimality score is based on the frequency distribution of the scores in the normal popula-

tion, defining as optimal all the scores found in at least 90% of a cohort of low-risk, typically developing infants assessed at different ages. Each item is scored separately, from 0 to 3, and the individual scores can be added to achieve a global optimality score. The global score can range from a minimum of 0 (if all the items score 0) to a maximum score of 78 (if each item scores 3).

Global scores are reported as optimal if they are equal or above 73 at 9 to 12 months, or equal or above 70 and 67 at 6 months and 3 months respectively.^{4,5} The lower scores with decreasing age are due to a small number of items that follow the development of some activities related to trunk control.^{4,5} Since its introduction, the HINE has been used in different high- and low-risk populations, both for pre-term and for term-born infants, and proposed as a different option for prognosis, diagnosis, and rehabilitation.⁶⁻¹³

The aim of the present study was to critically review the existing literature and our experience with use of the HINE in infants at risk of CP.

METHOD

Search strategy

A comprehensive search was made of the MEDLINE, Embase, PsycINFO, and CINAHL electronic databases. The primary search terms 'Hammersmith Infant Neurological Examination' or 'HINE' or 'Hammersmith Neurological Examination' were combined with the keywords 'cerebral palsy' or 'CP' or 'motor impairment'.

Inclusion criteria

Studies were eligible for inclusion if they were written in English and human-based. All the studies using the HINE were first selected. As the aim of the study was to establish the value of the HINE in identifying early signs of neuro-

logical impairment and its prognostic validity in infants at risk of CP, we used the following selection criteria: use of the HINE in cohorts including children with CP; reporting details of the examination in the first year in patients at risk of CP; follow-up data of at least 2 years to have a measure of the presence and type of CP.

Exclusion criteria

Studies were excluded if they were case reports, or if they assessed progressive and/or neurodegenerative disease, or if they had unusual population demographics including a significant sex imbalance (males <30%) or unusually high or low rates of CP.³

Data extraction and analysis

The title and abstracts of the studies were independently examined for suitability by two authors (DMR, CB) and critically checked by a third independent reviewer (EM); conflicting viewpoints were discussed until consensus was reached. The selected papers were further subdivided into (1) studies identifying possible early signs of neurological impairment in infants with brain lesions at risk of CP; (2) studies establishing whether the HINE could predict the type and the severity of CP, comparing the prognostic value of the assessment with other techniques (ultrasound, magnetic resonance imaging [MRI], general movements); and (3) studies reporting early signs of neurological impairment in a cohort with an established diagnosis of CP.

Demographic variables collected included median/mean and range of gestational age, sex, age when the HINE was performed, and classification of CP. For each study the sensitivity, specificity, false positives, and false negatives were either directly extracted or calculated from extracted data.

RESULTS

A total of 26 studies⁶⁻³¹ were initially identified (Fig. 1). Sixteen of the 26 were excluded as they either did not

What this paper adds

- Review of the Hammersmith Infant Neurological Examination (HINE) in the early diagnosis of cerebral palsy (CP).
- The HINE can be reliably used to assess infants at neurological risk, both preterm and term born.
- The HINE identifies early signs of CP in infants with neonatal brain lesions.
- Longitudinal assessments will allow differentiation of transient and more permanent abnormalities.

include infants at risk of CP ($n=13$) or they did not provide details of early neuromotor assessments ($n=3$). Ten articles,⁶⁻¹⁵ comprising a total of 3452 children (831 term-born infants, 2621 preterm), met the inclusion criteria after a review of the full text including the use of the HINE in infants and children with or at risk of CP (Table I).

Studies identifying early neurological signs in infants with brain lesions

Three studies reported how sequential assessments using the HINE can identify early neurological signs in infants at risk of developing CP;^{9,13,14} Ricci et al.⁹ described the evolution of neurological signs during the first 6 months after birth in 15 infants with neonatal encephalopathy. All the children with persistent abnormalities on the items assessing axial and limb tone, movements, and vision developed CP. The other two papers^{13,14} also reported the most and the least predictive items for CP using the HINE sequentially between 3 months and 12 months. Movement quality and quantity were the most predictive at all ages, followed by tone items (upper limb, axial tone) in the first semester and reactions (forward parachute and arm protection) in the second semester. The least predictive items were those assessing cranial nerves.

Studies comparing the prognostic value of the HINE with other techniques

Seven papers^{6-10,12,15} provided additional information not only about whether the HINE could predict the presence

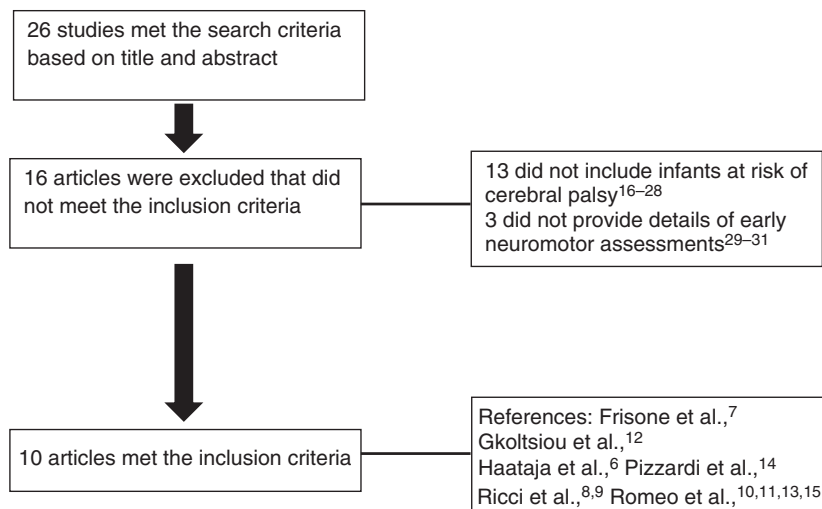


Figure 1: Flow chart for process of article inclusion.

Table 1: Study characteristics

Study	Population studied	n	Sex male (%)	Gestation (wk) mean/median (range)	Corrected age at HINE assessment (mo)	Outcome (% of CP)	Classification of CP	Correlation suboptimal HINE scores ^a vs CP (Se %, Sp %)	False positive, n (%)	False negative, n (%)
Haataja et al. ⁶	Hypoxic-ischaemic encephalopathy	53	29 (55)	Term	9-14	45	1H, 1D, 19Q, 3MD	Cut-off score 73 Se 100%; Sp 91%	3-4 (6-7)	0
Frisone et al. ⁷	Preterm infants (<31wks)	74	NR	27.5 (24-30.5)	6-15	12	2H, 3D, 2Q, 2Hy	Cut-off score 64 Se 98%; Sp 85%	2 (3)	1 (1)
Ricci et al. ⁸	Neonatal encephalopathy	15	10 (67)	Term	6	100	6Q, 9 MD	NR	0	0
Ricci et al. ⁹	Cystic periventricular leukomalacia	24	NR	1 term; 23 preterm (30.4; 26-35)	6-9	75	8D, 10Q	Cut-off score 60 Se 94%; Sp 100%	0	1 (4)
Romeo et al. ¹⁰	Preterm infants (<37wks)	903	496 (55)	34.5 ± 2.3	3	6	13H, 25D, 18Q, 1MD	Cut-off score 57 Se 96%; Sp 87%	113 (12) (54% of the 113 had mild disability)	2 (<1)
Pizzardi et al. ¹⁴	Preterm infants (<37wks) and neonatal encephalopathy	658	NR	108 term; 550 preterm (34.8 ± 2.14)	3, 6, 9, 12	11	NR	NR	NR	NR
Romeo et al. ¹¹	CP	70	45 (64)	13 term; 57 preterm (32; 26-36)	3, 6, 9, 12	100	19H, 26D, 20Q, 5MD	NA	NA	NA
Gkoltisiou et al. ¹²	Kernicterus	11	6 (54)	5 term; 6 preterm (35; 27-36)	12-18	64	7MD	Cut-off score 73 Se 100%; Sp 50%	2 (18)	0
Romeo et al. ¹³	Preterm infants (<32wks)	103	56 (54)	29.2 (25-31)	3, 6, 9, 12	18	4H, 5D, 10Q	3mo cut-off score 50 Se 93%; Sp 100% 6mo cut-off score 52 Se 93%; Sp 100% 9mo cut-off score 59 Se 93%; Sp 95% 12mo cut-off score 60 Se 95%; Sp 95%	0-4 (0-4)	1 (1)
Romeo et al. ¹⁵	NICU population (preterm and term born)	1541	816 (53)	638 term; 903 preterm (25-36)	3, 6, 9, 12	4.5	19H, 26D, 20Q, 5MD	3mo cut-off score 56 Se 96%; Sp 85% 6mo cut-off score 59 Se 90%; Sp 89% 9mo cut-off score 62 Se 90%; Sp 91% 12mo cut-off score 65 Se 90%; Sp 90%	148-221 (10-14)	3-7 (<1)

^aSuboptimal global cut-off scores according to each study. HINE, Hammersmith Infant Neurological Examination; CP, cerebral palsy; Se, sensitivity; Sp, specificity; H, hemiplegia; D, diplegia; Q, quadriplegia; MD, movement disorder; Hy, hypotonic CP; NR, not reported; NA, not applicable; NICU, neonatal intensive care unit.

of CP but also about its type and severity. These papers also compared the prognostic value of the HINE with imaging techniques, namely ultrasound in four of the seven papers^{7,9,10,15} and MRI in the other three.^{7,8,12} Most of these studies focused on preterm infants. Frisone et al.⁷ reported 74 preterm infants assessed between 9 months and 18 months. The infants who scored less than 52 on the HINE were unable to walk or even to sit unsupported at 2 years. Ultrasound was used to identify different subgroups according to lesions. Two of them had cystic periventricular leukomalacia who presented early suboptimal scores with severe motor impairment at 24 months. Other ultrasound abnormalities (marked ventricular dilatation, porencephaly, atrophy), in contrast, had both suboptimal and optimal HINE scores and both normal/abnormal outcomes (false positives and false negatives). Normal scans or minor lesions were associated with optimal scores on the HINE and normal outcome. No correlation between the prognostic value of ultrasound and the HINE was provided.

The correlation between severe early abnormalities and severe outcome in children with cystic periventricular leukomalacia was also reported in a cross-sectional study.⁹ Using the HINE in 24 infants with cystic periventricular leukomalacia at 6 to 9 months, the authors found that increased neck and trunk extensor tone, and a posture of flexed arms and extended legs, abnormal arm protection and forward parachute reaction between 6 months and 9 months were always associated with the inability to sit unsupported at 2 years, while truncal hypotonia and extended arms and legs were associated with unsupported sitting but not walking. A global score below 40 on the HINE was always associated with severe motor impairment (inability to sit independently at 2y), while scores between 41 and 60 were associated with less severe motor impairment (sitting but not walking at 2y). Scores greater than 60 were always associated with normal outcome. Children with severe early abnormalities on the HINE and CP were generally associated with lesions posterior to the trigone, and rarely (1/4) with lesions localized in the areas anterior to the trigone. The imaging helped to show that the variability of HINE scores and outcome was related to the site of the lesions. Another study¹⁰ described the possible early recognition of unilateral and bilateral CP using the HINE in 903 preterm infants in association with general movements and ultrasound. Ultrasound had the lowest correlation with CP compared with the HINE and general movement assessment. The integrated use of general movements and the HINE was the best predictor of CP and its severity. The integrated use of these tools improved prognostic accuracy at 3 months; absent fidgety and a HINE global score greater than 50 were highly suggestive of a hemiplegia, whereas absent fidgety and scores less than 50 on the HINE were associated with mild to severe CP (diplegia or quadriplegia).

In the largest study so far, Romeo et al.¹⁵ longitudinally assessed 1541 infants discharged from a neonatal intensive

care unit, both preterm and term born, using the HINE at 3 months, 6 months, 9 months, and 12 months with a motor outcome at 2 years. Global scores of not more than 56 at 3 months had a high (~90%) sensitivity and specificity for the development of CP, and scores less than 40 were only found in children who developed severe CP. The presence of mild disability (infants with no CP but with a low psychomotor developmental index and/or mild neurological signs) could be associated with HINE scores both in normal and in abnormal ranges. The HINE scores were not strictly associated with the pattern of ultrasound findings. No correlation between the prognostic value of ultrasound and the HINE was provided.

The remaining three studies used the HINE in association with neonatal MRI.^{7,8,12} In two studies in infants with hypoxic-ischaemic encephalopathy,^{7,8} the combination of the HINE and MRI helped to provide more accurate prognostic information than the individual tools. Normal neonatal MRI or moderate white matter lesions were always associated with optimal HINE scores (>73) and normal motor outcome; at the other end of the spectrum, severe basal ganglia lesions were associated with suboptimal HINE scores (<40), with abnormalities on the items assessing axial and limb tone, movements, and vision. All these infants developed severe CP and none achieved independent sitting.

Less severe groups of lesions had, in contrast, variable HINE findings and outcomes. In the children with minimal and moderate basal ganglia lesions, the HINE helped to distinguish between those with optimal scores and normal outcome, and others with suboptimal scores who often (75%) presented with motor impairment (sits independently but does not walk). In infants with severe white matter lesions but no basal ganglia involvement, the HINE performed from 6 months onwards helped to identify those with moderate motor impairment; however, there were false-negative findings on the HINE performed around the age of 3 months. Patients with this type of lesion had a peculiar maturational neurological pattern. While in the neonatal period there were obvious signs of neurological impairment with axial and limb hypotonia,⁸ limb tone appeared to normalize after 5 to 6 weeks and throughout the first few months, but was found to be increased from the age of 6 months. All these infants developed CP, even though they all achieved the ability to sit unsupported at 2 years and in some cases also to walk with support.

The remaining study reported clinical and neuroradiological patterns of 11 infants at risk of kernicterus.¹² In this study, neurological and MRI assessments were not systematically performed at the same age in the infants included. It is therefore not possible to reach a definite conclusion about the relationship between MRI findings, the HINE, and motor outcome.

Studies reporting early signs of neurological impairment in a cohort with an established CP diagnosis

Only one paper was included in this group of studies.¹¹ The authors correlated retrospectively HINE scores to

Gross Motor Function Classification System (GMFCS) levels in infants with CP, showing a significant negative correlation: all infants scoring greater than 60 were in level I; those scoring between 48 and 60 were in levels I and II; and those with lowest scores (<48) presented a severe motor function development (GMFCS levels IV and V). The authors concluded that the HINE could be used to identify infants with severe CP, with possible differences between diplegia and quadriplegia not only in the global scores but even in specific items such as tone (scarf sign, popliteal angle, adductors, pull to sit, ventral suspension) and posture (trunk and leg in sitting), with better scores for infants with diplegia. Although infants with hemiplegia scored much higher than those with diplegia and quadriplegia in global scores and in all subsections, they showed an overlap of scores with those infants with a normal outcome, demonstrating that the HINE is not a sensible tool in identifying unilateral impairment.

Accuracy of prediction of CP

The quantitative outcomes of accuracy of prediction of CP (sensitivity, specificity, false positives, and false negatives) from the studies are illustrated in Table I.

DISCUSSION

The review of the published studies suggests that the HINE is a useful tool in infants at risk of developing CP, in terms of predictive validity and description of early signs. The examination has been used in two ways. First, some studies mainly focused on the use of an optimality score that proved to be a reliable tool in a research setting. Specific cut-off scores for prediction of CP during the first year of age have been reported both in preterm and in term-born high-risk infants. Infants with global scores ≤ 56 at 3 months and ≤ 65 at 12 months showed a high (~90%) sensitivity and specificity for the development of CP, with scores <40 only found in association with severe CP.

Second, other studies used a more clinical approach, providing information on the diagnostic and prognostic value of individual clinical signs or identifying clinical patterns, predictive of abnormal outcome. The clinical signs that were more often associated with severe CP were abnormal posture, persistent abnormal axial (increased neck and trunk extensor tone) and limb tone (flexed arms and extended legs), and abnormal arm protection and forward parachute reaction during the second semester. These abnormalities can not only predict the development of CP but also provide an estimate of the functional level, as these early abnormalities can predict those infants who will not reach independent sitting and subsequent milestones. Specific items in the tone (scarf sign, popliteal angle, adductors, pull to sit, ventral suspension) and posture (trunk and leg in sitting) sections also helped to distinguish between diplegia and quadriplegia, with overall better global scores for infants with diplegia.

The value of movement quality and quantity in the HINE is, of course, limited compared with more detailed

observation of movements, such as general movements. However, when evaluated as part of a more general assessment of different aspects of neurological function, even a simplified assessment of movements showed a high prediction of motor outcome in a high-risk population.¹¹

No systematic comparison of the values of the HINE and imaging was performed. This was because the aim of the published studies was not to suggest that the clinical examination should be a substitute for detailed MRI studies, but to show how the HINE can provide additional information on the type and severity of different aspects of neurological impairment associated with the patterns of lesions generally observed in preterm and term infants with hypoxic-ischaemic encephalopathy. Those infants with severe patterns of lesions, such as severe basal ganglia involvement, cystic periventricular leukomalacia, or severe haemorrhages, showed severe patterns of neurological impairment with persistent motor cranial nerve, visual, and motor abnormalities during the first months of age, that were predictive of similar impairment at 2 years and later. The correlation between severity of MRI patterns and distinct patterns of clinical abnormalities can be important, especially in centres where MRI may not be readily available.

A meta-analysis of the predictive value of the studies using the HINE showed excellent sensitivity. False-positive results of the HINE were reported in few cases. These infants, despite showing some abnormalities on the HINE at 6 months, such as reduced axial tone or abnormal movements, did not develop CP. It is of interest, however, that global suboptimal scores, when not associated with CP, were found to be associated with minor neurological signs or low psychomotor development.¹⁵

The integrated approach with imaging helped to identify the subgroups at risk of false negatives. False negatives, namely infants with optimal HINE scores and CP, were also reported in a very low number of cases, mainly in infants with diffuse white matter lesions but normal basal ganglia. Children with hemiplegia were also difficult to identify during the first year of age using the HINE, as they reported scores similar to those with a normal outcome.

CONCLUSION

Neurological assessment is one of the clinical tools used to monitor development in infants with CP. Other methods are available, such as the Amiel-Tison Neurological Assessment and the Touwen Infant Neurological Examination.³ The HINE is easily performed and accessible to all clinicians; it has good interobserver reliability, even in inexperienced staff. One of the benefits compared with other tools is that the HINE not only identifies children at risk of CP but also often provides additional information on the type and severity of the motor sequelae. Furthermore, as the assessment includes several aspects of neurological functions, including cranial nerve assessment, posture, movements, tone, reflexes, and behaviour, it often allows

identification of early abnormal signs related to other aspects of neurological function such as cerebral visual impairment or feeding abnormalities; it therefore also allows better definition of the overall severity of CP, not limited to motor impairment. This appears to be particularly important as the early identification of such disabilities can help in planning appropriate intervention specifically aimed at the aspects of neurological function involved, rather than a general indication of intervention related to the presence of lesions.

The sequential use of the HINE allows clinicians to follow longitudinally high-risk infants during the first year of

corrected age, providing specific cut-off scores at different ages and identifying early signs of CP.^{11,13–15}

These results therefore strongly suggest that the HINE should be used to assess infants at neurological risk, both preterm and term born, from 3 months to 24 months. Longitudinal assessments will allow differentiation of transient and more permanent abnormalities, and help in planning appropriate intervention.

ACKNOWLEDGEMENTS

The authors have stated that they had no interests that might be perceived as posing a conflict or bias.

REFERENCES

- Bax M, Goldstein M, Rosenbaum P, et al.; Executive Committee for the Definition of Cerebral Palsy. Proposed definition and classification of cerebral palsy, April 2005. *Dev Med Child Neurol* 2005; **47**: 571–76.
- Rosenbaum P, Paneth N, Leviton A, et al. A report: the definition and classification of cerebral palsy April 2006. *Dev Med Child Neurol* 2007; **109** (Suppl.): 8–14.
- Bosanquet M, Copeland L, Ware R, Boyd R. A systematic review of tests to predict cerebral palsy in young children. *Dev Med Child Neurol* 2013; **55**: 418–26.
- Haataja L, Mercuri E, Regev R, et al. Optimality score for the neurologic examination of the infant at 12 and 18 months of age. *J Pediatr* 1999; **135**: 153–61.
- Haataja L, Cowan F, Mercuri E, Bassi L, Guzzetta A, Dubowitz L. Application of a scorable neurologic examination in healthy term infants aged 3 to 8 months. *J Pediatr* 2003; **143**: 546.
- Haataja L, Mercuri E, Guzzetta A, et al. Neurologic examination in infants with hypoxic-ischemic encephalopathy at age 9 to 14 months: use of optimality scores and correlation with magnetic resonance imaging findings. *J Pediatr* 2001; **138**: 332–37.
- Frisone MF, Mercuri E, Laroche S, et al. Prognostic value of the neurologic optimality score at 9 and 18 months in preterm infants born before 31 weeks' gestation. *J Pediatr* 2002; **140**: 57–60.
- Ricci D, Guzzetta A, Cowan F, et al. Sequential neurological examinations in infants with neonatal encephalopathy and low apgar scores: relationship with brain MRI. *Neuropediatrics* 2006; **37**: 148–53.
- Ricci D, Cowan F, Pane M, et al. Neurological examination at 6 to 9 months in infants with cystic periventricular leukomalacia. *Neuropediatrics* 2006; **37**: 247–52.
- Romeo DM, Guzzetta A, Scoto M, et al. Early neurologic assessment in preterm-infants: integration of traditional neurologic examination and observation of general movements. *Eur J Paediatr Neurol* 2008; **12**: 183–89.
- Romeo DM, Cioni M, Scoto M, Mazzone L, Palermo F, Romeo MG. Neuromotor development in infants with cerebral palsy investigated by the Hammersmith Infant Neurological Examination during the first year of age. *Eur J Paediatr Neurol* 2008; **12**: 24–31.
- Gkoltsiou K, Tzoufi M, Counsell S, Rutherford M, Cowan F. Serial brain MRI and ultrasound findings: relation to gestational age, bilirubin level, neonatal neurologic status and neurodevelopmental outcome in infants at risk of kernicterus. *Early Hum Dev* 2008; **84**: 829–38.
- Romeo DM, Cioni M, Scoto M, Pizzardi A, Romeo MG, Guzzetta A. Prognostic value of a scorable neurological examination from 3 to 12 months post-term age in very preterm infants: a longitudinal study. *Early Hum Dev* 2009; **85**: 405–08.
- Pizzardi A, Romeo DM, Cioni M, Romeo MG, Guzzetta A. Infant neurological examination from 3 to 12 months: predictive value of the single items. *Neuropediatrics* 2008; **39**: 344–46.
- Romeo DM, Cioni M, Palermo F, Cilauro S, Romeo MG. Neurological assessment in infants discharged from a neonatal intensive care unit. *Eur J Paediatr Neurol* 2013; **17**: 192–98.
- Romeo DM, Cioni M, Guzzetta A, et al. Application of a scorable neurological examination to near-term infants: longitudinal data. *Neuropediatrics* 2007; **38**: 233–8.
- Luciano R, Baranello G, Masini L, et al. Antenatal post-hemorrhagic ventriculomegaly: a prospective follow-up study. *Neuropediatrics* 2007; **38**: 137–42.
- Haataja L, Mercuri E, Cowan F, Dubowitz L. Cranial ultrasound abnormalities in full term infants in a postnatal ward: outcome at 12 and 18 months. *Arch Dis Child Fetal Neonatal Ed* 2000; **82**: F128–33.
- Fowler EA, Becker DB, Pilgram TK, Noetzel M, Epstein J, Kane AA. Neurologic findings in infants with deformational plagiocephaly. *J Child Neurol* 2008; **23**: 742–47.
- Karagianni P, Kyriakidou M, Mitsiakos G, et al. Neurological outcome in preterm small for gestational age infants compared to appropriate for gestational age preterm at the age of 18 months: a prospective study. *J Child Neurol* 2010; **25**: 165–70.
- Lind A, Lapinleimu H, Korkman M, Lehtonen L, Parkkola R, Haataja L, PIPARI Study Group. Five-year follow-up of prematurely born children with postnatally developing caudothalamic cysts. *Acta Paediatr* 2010; **99**: 304–07.
- Leppänen M, Ekholm E, Palo P, et al.; PIPARI Study Group. Abnormal antenatal Doppler velocimetry and cognitive outcome in very-low-birth-weight infants at 2 years of age. *Ultrasound Obstet Gynecol* 2010; **36**: 178–85.
- Maunu J, Lehtonen L, Lapinleimu H, et al.; PIPARI Study Group. Ventricular dilatation in relation to outcome at 2 years of age in very preterm infants: a prospective Finnish cohort study. *Dev Med Child Neurol* 2011; **53**: 48–54.
- Karagianni P, Tsakalidis C, Kyriakidou M, et al. Neuro-motor outcomes in infants with bronchopulmonary dysplasia. *Pediatr Neurol* 2011; **44**: 40–46.
- Lind A, Parkkola R, Lehtonen L, et al.; PIPARI Study Group. Associations between regional brain volumes at term-equivalent age and development at 2 years of age in preterm children. *Pediatr Radiol* 2011; **41**: 953–61.
- Karagianni P, Rallis D, Kyriakidou M, Tsakalidis C, Pratsiou P, Nikolaidis N. Correlation of brain ultrasonography scans to the neuromotor outcome of very-low-birth-weight infants during the first year of life. *J Child Neurol* 2014; **29**: 1429–35.
- Mathew P, Pannek K, Snow P, et al. Maturation of corpus callosum anterior midbody is associated with neonatal motor function in eight preterm-born infants. *Neural Plast* 2013; **2013**: 359532.
- Amess P, McFerran C, Khan Y, Rabe H. Early prediction of neurological outcome by term neurological examination and cranial ultrasound in very preterm infants. *Acta Paediatr* 2009; **98**: 448–53.
- Dogra DP, Majumdar AK, Sural S, Mukherjee J, Mukherjee S, Singh A. Toward automating Hammersmith pulled-to-sit examination of infants using feature point based video object tracking. *IEEE Trans Neural Syst Rehabil Eng* 2012; **20**: 38–47.
- Dogra DP, Majumdar AK, Sural S, Mukherjee J, Mukherjee S, Singh A. Analysis of adductors angle measurement in Hammersmith infant neurological examinations using mean shift segmentation and feature point based object tracking. *Comput Biol Med* 2012; **42**: 925–34.
- Dogra DP, Badri V, Majumdar AK, et al. Video analysis of Hammersmith lateral tilting examination using Kalman filter guided multi-path tracking. *Med Biol Eng Comput* 2014; **52**: 759–72.